RadiologyInfo.org
For patients

What are the benefits of CT scans?

Computed tomography (CT or CAT scan) ranks as one of the top five medical developments in the last 50 years, according to most medical surveys. CT has proven so valuable as a medical diagnostic tool that the 1979 Nobel Prize in Medicine was awarded to the inventors.

How it works

X-ray image showing internal body structures

Both CT and conventional x-rays take pictures of internal body structures. In conventional x-rays, the structures overlap. For example, the ribs overlay the lung and heart. In an x-ray, structures of medical concern are often obscured by other organs or bones, making diagnosis difficult.

CT image showing internal body structures

In a CT image, overlapping structures are eliminated, making the internal anatomy more apparent.

During CT imaging, an x-ray tube rotates around the patient so that multiple images are collected from many angles. These images are stored in a computer that analyzes them to create a new image with the overlying structures removed.

CT images allow radiologists and other physicians to identify internal structures and see their shape, size, density, and texture. This detailed information can be used to determine if there is a medical problem, provide the extent and exact location of the problem, and reveal other important details that can help the physician determine the best treatment. The images may also show if no abnormality is present.

Copyright© 2024, RadiologyInfo.org

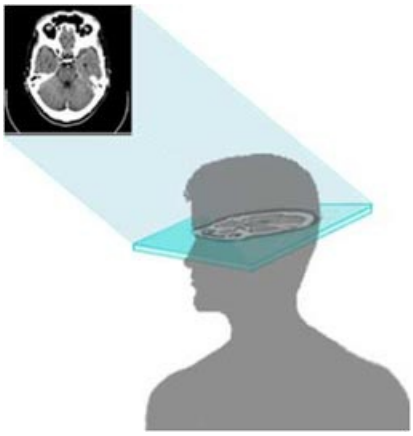

A CT scan that shows no abnormality still provides useful data. The information aids the health care provider by focusing attention away from unnecessary medical concerns.

Modern CT scanners acquire this information in seconds – sometimes in fractions of a second – depending on the examination.

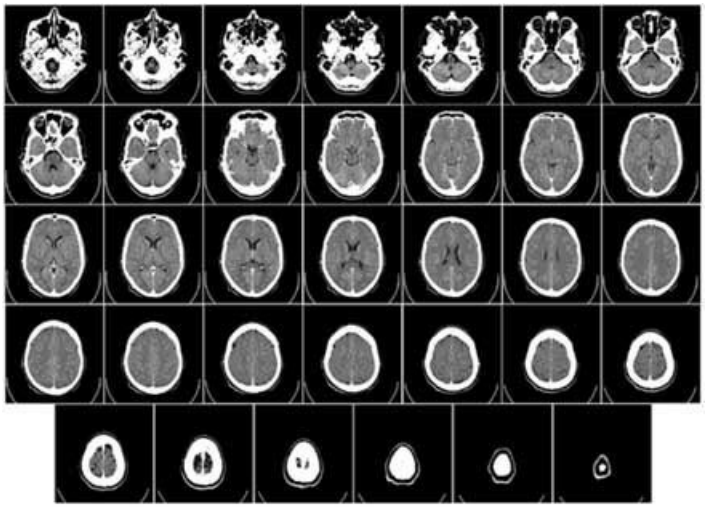

Benefits

Benefits of CT include more effective medical management by:

- determining when surgeries are necessary
- reducing the need for exploratory surgeries
- improving cancer diagnosis and treatment
- reducing the length of hospitalizations
- guiding treatment of common conditions such as injury, cardiac disease and stroke
- improving patient placement into appropriate areas of care, such as intensive care units

In an emergency room, patients can be scanned quickly so doctors can rapidly assess their condition. Emergency surgery might be necessary to stop internal bleeding. CT images show the surgeons exactly where to operate. Without this information, the success of surgery is greatly compromised. The risk of radiation exposure from CT is very small compared with the benefit of a well-

Copyright© 2024, RadiologyInfo.org

planned surgery.

CT scanning provides medical information that is different from other imaging examinations, such as ultrasound, MRI, SPECT, PET or nuclear medicine. Each imaging technique has advantages and limitations. The principal advantages of CT are its abilities to:

1. Rapidly acquire images.
2. Provide clear and specific information.
3. Image a small portion or all the body during the same examination.

No other imaging procedure combines these advantages into a single session.

Disclaimer

This information is copied from the RadiologyInfo Web site (http://www.radiologyinfo.org) which is dedicated to providing the highest quality information. To ensure that, each section is reviewed by a physician with expertise in the area presented. All information contained in the Web site is further reviewed by an ACR (American College of Radiology) - RSNA (Radiological Society of North America) committee, comprising physicians with expertise in several radiologic areas.

However, it is not possible to assure that this Web site contains complete, up-to-date information on any particular subject. Therefore, ACR and RSNA make no representations or warranties about the suitability of this information for use for any particular purpose. All information is provided "as is" without express or implied warranty.

Please visit the RadiologyInfo Web site at **http://www.radiologyinfo.org** to view or download the latest information.

Note: Images may be shown for illustrative purposes. Do not attempt to draw conclusions or make diagnoses by comparing these images to other medical images, particularly your own. Only qualified physicians should interpret images; the radiologist is the physician expert trained in medical imaging.

Copyright

This material is copyrighted by either the Radiological Society of North America (RSNA), 820 Jorie Boulevard, Oak Brook, IL 60523-2251 or the American College of Radiology (ACR), 1891 Preston White Drive, Reston, VA 20191-4397. Commercial reproduction or multiple distribution by any traditional or electronically based reproduction/publication method is prohibited.

Copyright ® 2024 Radiological Society of North America, Inc.