Cranial Ultrasound

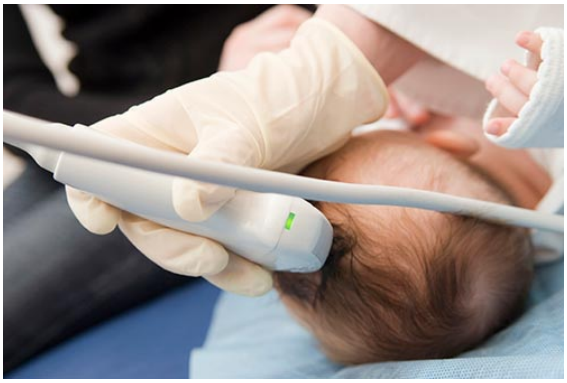

Ultrasound imaging of the head uses sound waves to produce pictures of the brain and cerebrospinal fluid. It is usually performed on infants, whose skulls have not completely formed. A transcranial Doppler ultrasound evaluates blood flow in the brain's major arteries. Ultrasound is safe, noninvasive, and does not use ionizing radiation.

This procedure requires little to no special preparation. Your doctor will tell you how to prepare. If you are an adult, you should not use nicotine-based products that may cause blood vessels to constrict. Leave jewelry at home and wear loose, comfortable clothing. You may need to change into a gown for the procedure.

What is cranial ultrasound?

There are two main types of cranial ultrasound:

- *Head ultrasound* that examines the structures of the brain
- *Transcranial Doppler* that evaluates the flow of blood to the brain.

Head Ultrasound

A head ultrasound exam produces images of the brain. It also shows the cerebrospinal fluid (http://www.radiologyinfo.org) that surrounds the brain and is contained within its ventricles (http://www.radiologyinfo.org) . Since ultrasound waves do not pass through bone easily, this exam is usually performed on infants, whose skulls have not completely formed. The gaps between those skull bones provide a "window" that allows the sound waves to freely pass into and back from the brain. The technologist places the ultrasound probe and some gel on one of those head regions without bone, often called “soft spots.”

Transcranial Doppler

A transcranial Doppler (TCD) ultrasound evaluates both the direction and velocity of the blood flow in the major cerebral arteries of the brain. Doctors also use this exam during surgery to monitor blood flow in the brain. Doctors may use TCD alone or with magnetic resonance imaging (http://www.radiologyinfo.org) (MRI), magnetic resonance angiograph (http://www.radiologyinfo.org) (MRA), or computed tomography (http://www.radiologyinfo.org) (CT).

Ultrasound imaging is a noninvasive medical test that helps physicians diagnose and treat medical conditions. It is safe and painless. It produces pictures of the inside of the body using sound waves. Ultrasound imaging is also called sonography (http://www.radiologyinfo.org) . It uses a small probe called a transducer and gel placed directly on the skin. High-frequency sound waves travel from the probe through the gel into the body. The probe collects the sounds that bounce back. A computer uses those sound waves to create an image. Ultrasound exams do not use radiation (http://www.radiologyinfo.org) (x-rays (http://www.radiologyinfo.org)). Because ultrasound captures images in real-time, it can show the structure and movement of the body's internal organs. The images can also show blood flowing through blood vessels.

What are some common uses of the procedure?

Copyright© 2026, RadiologyInfo.org

Head ultrasound is a routine exam for infants who were born prematurely. The procedure is used to screen for brain conditions associated with prematurity, such as bleeding or brain tissue damage as described below. If detected, follow-up ultrasound exams will be performed.

In infants, head ultrasound is used to:

- evaluate for hydrocephalus (http://www.radiologyinfo.org) , or an enlargement of the ventricles, a condition that can have a number of causes.
- detect bleeding within the brain tissue or the ventricles. The latter condition is called intraventricular hemorrhage (IVH).
- assess whether there is damage to the white matter brain tissue surrounding the edges of the ventricles, a condition known as periventricular leukomalacia (PVL).
- evaluate for congenital abnormalities.
- locate the site of an infection or tumor.

In adults, head ultrasound is used to locate and evaluate tumor masses during brain surgery, facilitating their safe removal.

Transcranial Doppler ultrasound is used to assess the risk of stroke in adults and children with sickle cell disease. It is also used to measure conditions affecting blood flow to and within the brain, such as:

- Stenosis (http://www.radiologyinfo.org) : a narrowing of a segment of a vessel, most commonly due to atherosclerosis (hardening of the arteries).
- Vasospasm (http://www.radiologyinfo.org) : a temporary narrowing of a vessel, usually a reaction to blood being present in the spinal fluid spaces surrounding the brain. This condition is known as subarachnoid hemorrhage (SAH).

Who interprets the results and how do I get them?

A radiologist, a doctor trained to supervise and interpret radiology exams, will analyze the images. The radiologist will send a signed report to the doctor who requested the exam. Your doctor will then share the results with you. In some cases, the radiologist may discuss results with you after the exam.

You may need a follow-up exam. If so, your doctor will explain why. Sometimes a follow-up exam further evaluates a potential issue with more views or a special imaging technique. It may also see if there has been any change in an issue over time. Follow-up exams are often the best way to see if treatment is working or if a problem needs attention.

What are the benefits vs. risks?

Benefits

- Most ultrasound scanning is noninvasive (no needles or injections).
- Occasionally, an ultrasound exam may be temporarily uncomfortable, but it should not be painful.
- Ultrasound is widely available, easy to use, and less expensive than most other imaging methods.
- Ultrasound imaging is extremely safe and does not use radiation.
- Ultrasound scanning gives a clear picture of soft tissues that do not show up well on x-ray images.

Risks

- Standard diagnostic ultrasound (http://www.radiologyinfo.org) has no known harmful effects on humans.

What are the limitations of cranial ultrasound?

Copyright© 2026, RadiologyInfo.org

Ultrasound examinations are very sensitive to motion, and an active or crying child will slow the examination process.

Large patients are more difficult to image by ultrasound, because greater amounts of tissue weaken the sound waves as they pass deeper into the body.

Exam results could be altered, due to:

- an open wound or recent surgical incision near the area being imaged.
- changes in blood flow pattern as a result of heart disease or irregular heart rhythms.

Disclaimer

This information is copied from the RadiologyInfo Web site (http://www.radiologyinfo.org) which is dedicated to providing the highest quality information. To ensure that, each section is reviewed by a physician with expertise in the area presented. All information contained in the Web site is further reviewed by an ACR (American College of Radiology) - RSNA (Radiological Society of North America) committee, comprising physicians with expertise in several radiologic areas.

However, it is not possible to assure that this Web site contains complete, up-to-date information on any particular subject. Therefore, ACR and RSNA make no representations or warranties about the suitability of this information for use for any particular purpose. All information is provided "as is" without express or implied warranty.

Please visit the RadiologyInfo Web site at **http://www.radiologyinfo.org** to view or download the latest information.

Note: Images may be shown for illustrative purposes. Do not attempt to draw conclusions or make diagnoses by comparing these images to other medical images, particularly your own. Only qualified physicians should interpret images; the radiologist is the physician expert trained in medical imaging.

Copyright

This material is copyrighted by either the Radiological Society of North America (RSNA), 820 Jorie Boulevard, Oak Brook, IL 60523-2251 or the American College of Radiology (ACR), 1891 Preston White Drive, Reston, VA 20191-4397. Commercial reproduction or multiple distribution by any traditional or electronically based reproduction/publication method is prohibited.

Copyright ® 2026 Radiological Society of North America, Inc.