
Galactography (Ductography)

This information is reviewed by a physician with expertise in the area presented and is further reviewed by committees from the American College of Radiology (ACR) and the Radiological Society of North America (RSNA), comprising physicians with expertise in several radiologic areas.

What is Galactography (Ductography)?

Galactography is an x-ray examination that uses mammography, a low-dose x-ray system for examining breasts, and a contrast material to obtain pictures, called galactograms, of the inside of the breast's milk ducts.

An x-ray (radiograph) is a noninvasive medical test that helps physicians diagnose and treat medical conditions. Imaging with x-rays involves exposing a part of the body to a small dose of ionizing radiation to produce pictures of the inside of the body. X-rays are the oldest and most frequently used form of medical imaging.

The breast is composed primarily of three structures: fat, lobules (that make the milk) and milk ducts (that carry the milk from the lobule to the nipple). While mammography, ultrasound and magnetic resonance imaging (MRI) are excellent ways to image the breast; they do not visualize the inside of the breast's milk ducts to the same degree as galactography.

What are some common uses of the procedure?

The most common use of galactography is to evaluate a woman who has a bloody or clear discharge from her breast nipple and an otherwise normal mammogram.

Galactography is typically NOT called for in women with the following conditions:

- A discharge that is milky, yellow, green, black or gray is usually not a cause for concern, especially if it comes from multiple ducts in the breast.
- A discharge that is from both breasts in a woman who has not had children may indicate a side effect from a drug, or may be related to a pituitary problem located in the brain.

- A minimal milky discharge from both breasts in a woman who has had children is not unusual, and only rarely is a cause for concern.

How should I prepare?

Very little preparation is necessary for this procedure. The only requirement is that the nipple not be squeezed prior to the exam, as sometimes there is only a small amount of fluid, and it is necessary to see where that fluid is coming from to perform the exam.

You should inform your physician of any medications you are taking and if you have any allergies, especially to barium or iodinated contrast materials. Also inform your doctor about recent illnesses or other medical conditions.

Always inform your doctor or x-ray technologist if there is any possibility that you are pregnant.

As in mammography, do not wear deodorant, talcum powder or lotion under your arms or on your breasts on the day of the exam. These can appear on the mammogram as calcium spots.

In addition, before the examination you will be asked to remove all jewelry and clothing above the waist and you will be given a gown or loose-fitting material that opens in the front.

What does the equipment look like?

This exam is performed using a mammography unit.

A mammography unit is a rectangular box that houses the tube in which x-rays are produced. The unit is used exclusively for x-ray exams of the breast, with special accessories that allow only the breast to be exposed to the x-rays. Attached to the unit is a device that holds and compresses the breast and positions it so images can be obtained at different angles.

Other equipment needed for this exam may include small wires called dilators, a small catheter, a plastic hollow tube, and a blunt-tipped needle that is inserted into the milk duct in the nipple to inject a tiny amount of contrast material.

How does the procedure work?

X-rays are a form of radiation like light or radio waves. X-rays pass through most objects, including the body. Once it is carefully aimed at the part of the body being examined, an x-ray machine produces a small burst of radiation that passes through the body, recording an image on photographic film or a special digital image recording plate.

Different parts of the body absorb the x-rays in varying degrees. Dense bone absorbs much of the radiation while soft tissue, such as muscle, fat and organs, allow more of the x-rays to pass through them. As a result, bones appear white on the x-ray, soft tissue shows up in shades of gray and air appears black.

In galactography, a small amount of contrast material is injected into the milk duct, and a mammogram is performed so that the inside of the milk duct can be seen.

If there is a filling defect (black area) in the milk duct, it often indicates a small mass. Most of these are papillomas, which are non-cancerous masses of the milk ducts. They may be pre-cancerous, and sometimes are removed. Less than 10 percent of filling defects will be cancer.

The galactogram will not only find the small mass, but will also show where it is located in the breast, to help the surgeon find the area.

In some cases, there are no filling defects. Rather, the ducts lead to cysts in the breast, a sign of fibrocystic change. These cysts may cause a bloody discharge, but generally are not worrisome.

How is the procedure performed?

This examination is usually done on an outpatient basis. However, some procedures may require admission. Please consult with your physician.

The patient is seated or placed on her back with the breast exposed. The nipple is cleansed, and a tiny amount of fluid is squeezed from the nipple to identify the duct with the discharge. The milk duct may be dilated to permit a small catheter (a plastic, hollow tube) or blunt-tipped needle to be inserted into the milk duct. Occasionally a warm towel will be placed on the breast to help the milk duct become more visible and to allow

easier access to the milk duct. A small amount of contrast material is then injected, and a mammogram is obtained. A second injection and mammogram may be performed.

You must hold very still and may be asked to keep from breathing for a few seconds while the x-ray picture is taken to reduce the possibility of a blurred image. The technologist will walk behind a wall or into the next room to activate the x-ray machine.

When the examination is completed, you will be asked to wait until the technologist or radiologist determines that all the necessary images have been obtained.

The procedure normally takes between 30 minutes and an hour.

What will I experience during and after the procedure?

The dilation of the milk duct can sometimes be uncomfortable; however it is usually not painful. The nipple may be squeezed to identify the milk duct with the discharge.

Who interprets the results and how do I get them?

A radiologist, a physician specifically trained to supervise and interpret radiology examinations, will analyze the images and send a signed report to your primary care or referring physician, who will discuss the results with you.

The report may be given directly to you at the time of the exam.

What are the benefits vs. risks?

Benefits

- Galactography can find small cancerous and non-cancerous masses that cannot be identified in any other way so that they may be removed at an early stage.
- A galactogram identifies the location of the tumors in the breast for the surgeon.
- No radiation remains in a patient's body after an x-ray examination.
- X-rays usually have no side effects in the diagnostic range.

Risks

- There is always a slight chance of cancer from exposure to radiation. However, the benefit of an accurate diagnosis far outweighs the risk.
- It is possible to injure the duct, either during the process of placing the catheter or while injecting contrast material. This almost always heals by itself.
- It is possible to miss the area of concern, or to put the catheter into the incorrect duct, potentially delaying diagnosis.
- There is always a possibility of infection of the breast, or mastitis, but this is uncommon.
- Women should always inform their doctor or x-ray technologist if there is any possibility that they are pregnant.

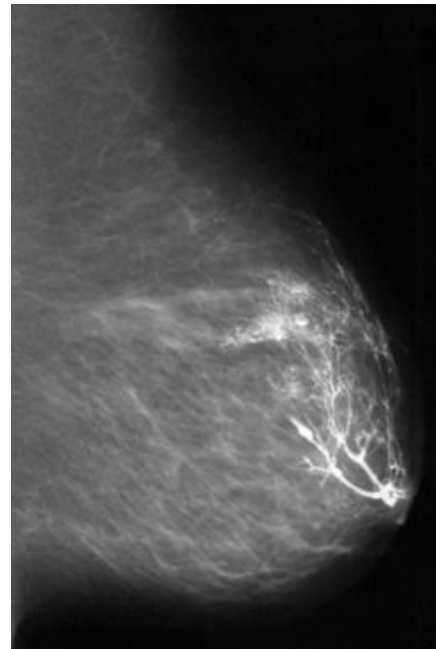
A Word About Minimizing Radiation Exposure

Special care is taken during x-ray examinations to use the lowest radiation dose possible while producing the best images for evaluation. National and international radiology protection councils continually review and update the technique standards used by radiology professionals.

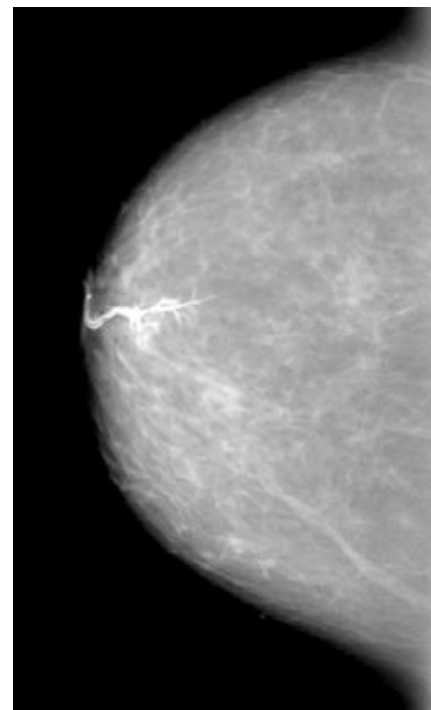
State-of-the-art x-ray systems have tightly controlled x-ray beams with significant filtration and dose control methods to minimize stray or scatter radiation. This ensures that those parts of a patient's body not being imaged receive minimal radiation exposure.

What are the limitations of Galactography?

If there is no discharge at the time of the exam, the duct cannot be identified, so the test cannot be performed. In addition, some ducts are quite small, and may not be able to be dilated. If the incorrect duct is injected, an incorrect diagnosis can be made. Not all breast tumors occur within the ducts, and a tumor may be present that is not identified on the galactogram.



Galactogram (side view)



Top-down view of a galactogram with a papilloma. The papilloma is the dark area in the middle of the white linear duct near the nipple.

Disclaimer:

This information is copied from the RadiologyInfo Web site (<http://www.radiologyinfo.org>) which is dedicated to providing the highest quality information. To ensure that, each section is reviewed by a physician with expertise in the area presented. All information contained in the Web site is further reviewed by an ACR (American College of Radiology) - RSNA (Radiological Society of North America) committee, comprising physicians with expertise in several radiologic areas.

However, it is not possible to assure that this Web site contains complete, up-to-date information on any particular subject. Therefore, ACR and RSNA make no representations or warranties about the suitability of this information for use for any particular purpose. All information is provided "as is" without express or implied warranty.

Please visit the RadiologyInfo Web site at <http://www.radiologyinfo.org> to view or download the latest information.

Note: Images are shown for illustrative purposes. Do not attempt to draw conclusions or make diagnoses by comparing these images to other medical images, particularly your own. Only qualified physicians should interpret images; the radiologist is the physician expert trained in medical imaging.

Copyright © 2009 Radiological Society of North America, Inc.
Send comments via email to: webmast2@rsna.org